



VETERINARY
MRI + RADIOTHERAPY
CENTER OF NEW JERSEY

Veterinary MRI and RT Center of New Jersey


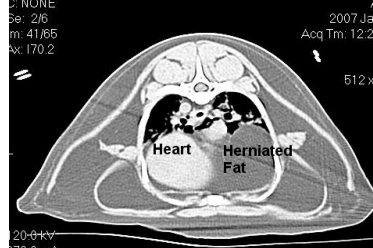
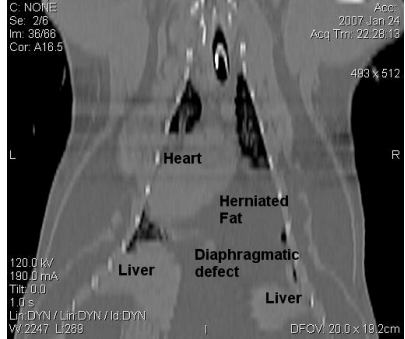
www.vetMRIRT.com

Case Report June 2008

CT for Dyspnea and Mass lesion

Case Summary – A ten year old MN DSH cat presented for a one month duration of occasional coughing, lethargy and mild dyspnea. On physical exam the pet was obese. Lung and cardiac sounds were reduced on the right. Survey radiographs revealed a mass in the right mid through caudal thorax. Neoplasia, abscess, cyst, granuloma, hematoma and sequestered fluid were considered as possible causes of the mass. A thoracic US was inconclusive.

Imaging- A thoracic CT was performed. No complications were encountered and “Connemara” recovered uneventfully. Cross sectional imaging and multiplanar reconstructions of affected area are shown below.

		
<p>Scout VD image shows mass in the right mid and caudal thorax</p>	<p>The axial CT image through the level of the heart and mass demonstrates the “mass” is fat density tissue similar to the subcutaneous fat in this obese patient.</p>	<p>2D reconstruction in the dorsal plane showing the herniated fat extending through the mid ventral diaphragm into the thorax and pericardial sac</p>

Imaging Diagnosis- Obesity. Pericardioperitoneal diaphragmatic hernia with a large amount of herniated falciform fat creating a mass effect in the right mid and caudal ventral thoracic regions.

Outcome- The prognosis is excellent based on the CT diagnosis. The owner elected to have the henia repaired surgically and the patient did well. Weight loss was also advised.

Please do not hesitate to contact our facility to discuss the value of a CT or MRI study for a particular patient prior to requesting an imaging study.

(Tel – 973 772-9902, Fax – 973 772-9904)

CT is the best modality to evaluate thoracic structures.

Cross sectional imaging eliminates the uncertainty due to overlapping structures inherent to interpreting radiographs.

A rapid helical CT scanner completes thoracic imaging in minutes.