

Veterinary MRI and RT Center of New Jersey



VETERINARY
MRI + RADIOTHERAPY
CENTER OF NEW JERSEY

Magnetic Resonance Cross sectional Imaging can be used to visualize lesions otherwise undetectable using standard radiographs.

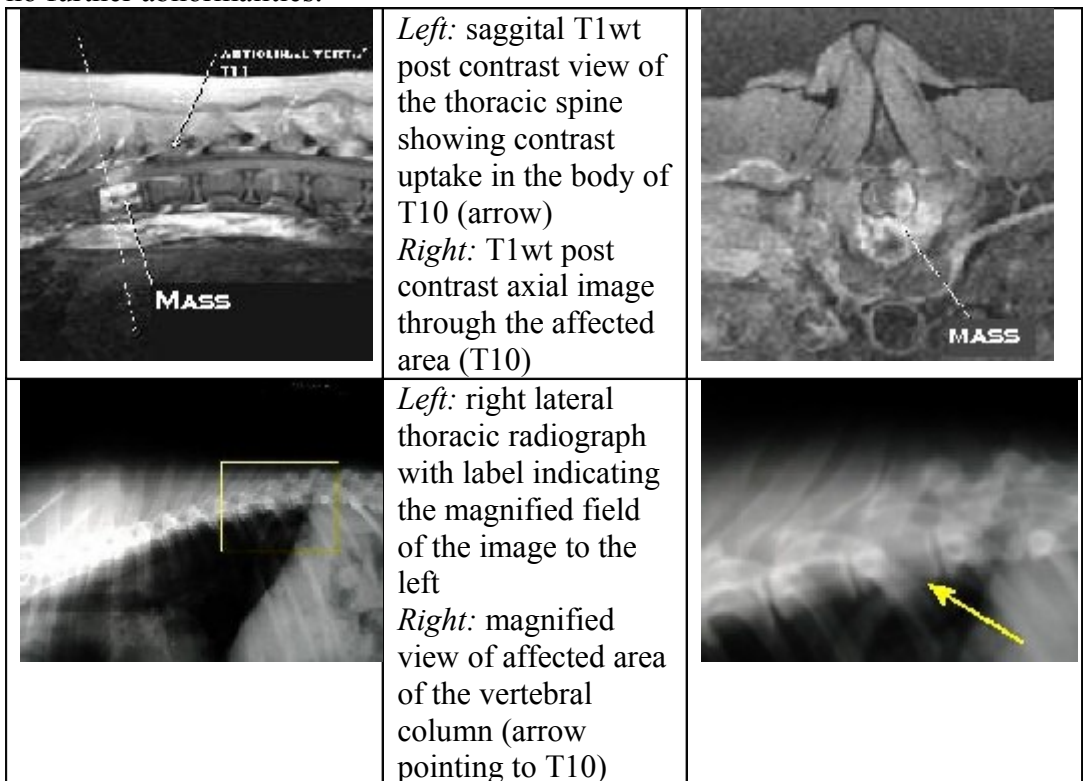
MRI can also be used to plan possible surgical intervention and help determine overall prognosis.

MRI can show visual changes in the spinal cord itself allowing additional prognostic value and is over a myelogram. The imaging itself is also noninvasive.

Case Report #1

Case Report 1: Vertebral Column Mass

Case Summary –An 8yr old spayed female mixed breed dog presented for magnetic resonance imaging of her spine from the 3rd thoracic vertebra to the lumbosacral junction. She was suffering from progressive ataxia and paresis for approximately 1 week prior to presentation that acutely worsened the night before. She was taking Previcox and glucosamine/chondroitin sulfate supplements at the time of the scan. The dog began with mild neck pain 10 days prior to presentation after a long walk with the owners. This responded to anti-inflammatory medications. Radiographs of the thoracolumbar spine showed moderate spondylosis from T12-L2 intervertebral spaces. Radiographs also revealed moderate osteoarthritic changes in the left coxofemoral joint. Preanesthetic workup revealed no further abnormalities.



Findings: A mass -like infiltrate was discovered involving the vertebral body, pedicles and portions of the adjacent ribs of T10. T10 was reduced in signal intensity and mildly enlarged on T1wt pre contrast and T2wt images and enhanced markedly after contrast administration. The spinal cord was markedly compressed by extension of proliferative tissue from the vertebral segment into the spinal canal of the segment. Focal areas of contrast enhancement were also noted in the bodies of L1 and L2, but the affected vertebra were normal in shape and size and no change in signal was seen in any of the non-contrast pulse sequences.

Imaging Diagnosis: Findings were consistent with primary bone tumor, most likely osteosarcoma arising from T10 with secondary spinal cord compression. Lower consideration was given to other primary bone tumors and much less likely metastatic neoplasia from an unidentified primary site. Changes in L1 and L2 may have represented areas of inflammation or possible early metastatic lesions.

Outcome: Due to the poor prognosis, rapid progression, and advanced state of disease, euthanasia was elected.

Please do not hesitate to contact our facility to discuss the value of a CT or MRI study for a particular patient prior to requesting an imaging study.

(Tel – 973 772-9902, Fax – 973 772-9904)