

Veterinary MRI and RT Center of New Jersey



VETERINARY

MRI + RADIO THERAPY
CENTER OF NEW JERSEY

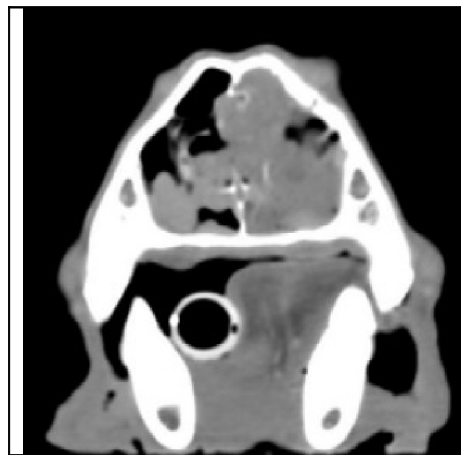
CT imaging is much less invasive than rhinoscopy and allows better overall evaluation of the nasal cavity and sinuses over nasal radiographs.

Radiation Therapy is very successful in treating many nasal tumors while preserving the pet's normal anatomy and aesthetics.

Case Report #7

Nasal Imaging and Radiation Therapy

Case Summary- An 11yr MN English Pointer presented initially for increased nasal sounds especially noted when sleeping. Rhinitis was suspected. The pet had not responded to antibiotics. The pet was being treated with oral steroids with incomplete success at the time of the scan.



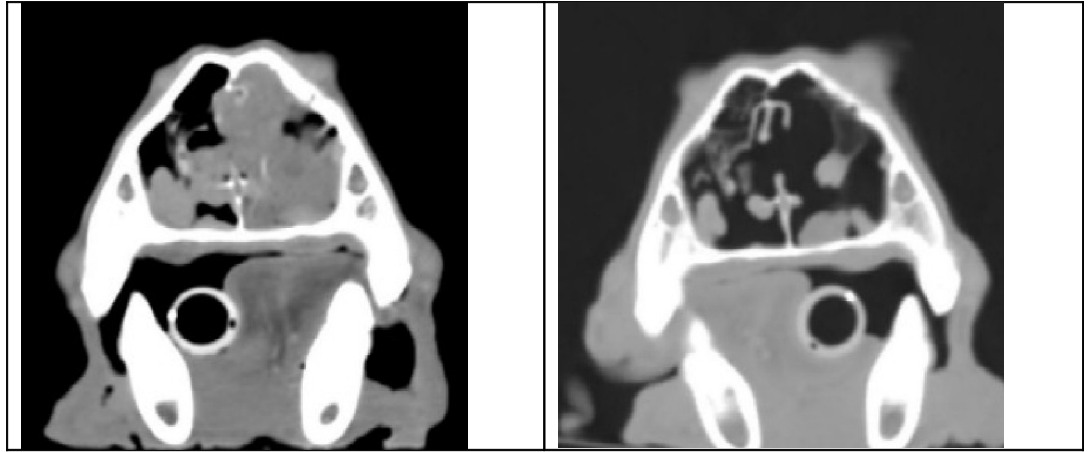
Left: axial CT images showing right nasal cavity soft tissue infiltrate with destruction of the nasal septum.

Findings: Computed Tomography (CT) of the nasal/sinus area showed soft tissue contrast enhancing soft tissue filling a majority of the right side of the nasal cavity along with complete filling of the right frontal sinus with non-contrast enhancing soft tissue attenuating fluid. There was loss of turbinate bone in the rostral portion of the nasal cavity and mid lateral portions of the right nasal cavity. The mass/fluid extended through portions of the nasal septum a few millimeters into the left side of the nasal cavity, but did not extend through the cribriform plate, subcutaneously or into the right retrobulbar region.

Imaging Diagnosis: Changes consistent with right sided primary nasal neoplasia or less likely chronic unilateral infectious or immune-mediated rhinitis, with secondary frontal sinusitis.

Outcome: Biopsy guided by the results of CT and endoscopy confirmed a diagnosis of nasal adenocarcinoma. The owner elected after further medical management to treat for the nasal cancer with external beam radiation therapy. The CT scan was used for radiation therapy planning. The patient received 54 Gray of 6MeV of photon radiation to an area collimated to his nasal mass and frontal sinus. He received the 54Gy dose in 18 fractions (300 centiGray each) over a period of one month. The only complication reported was some moderate irritation and crusting of the right eye (which was unavoidably in the treatment field, the left eye was spared outside the treatment field) which was successfully managed with topical medications. Below you will find the diagnostic CT (on the left) alongside a

3 month post radiation therapy follow up CT (right) which shows marked improvement. The nasal mass was markedly reduced in size and the frontal sinus was clear at that time. The only lingering effects were some nasal turbinate and nasal septal loss due to lysis from the previous mass, and temporary muzzle hair loss with subsequent gray hair regrowth of the skin in the treatment field.



*Please do not hesitate to contact our facility to discuss the value of a CT or MRI study for a particular patient prior to requesting an imaging study.
(Tel – 973 772-9902, Fax – 973 772-9904)*