

Veterinary MRI and RT Center of New Jersey



VETERINARY
MRI + RADIOTHERAPY
CENTER OF NEW JERSEY

CT is the best modality to evaluate thoracic structures.

Cross sectional imaging eliminates the uncertainty due to overlapping structures inherent to interpreting radiographs.

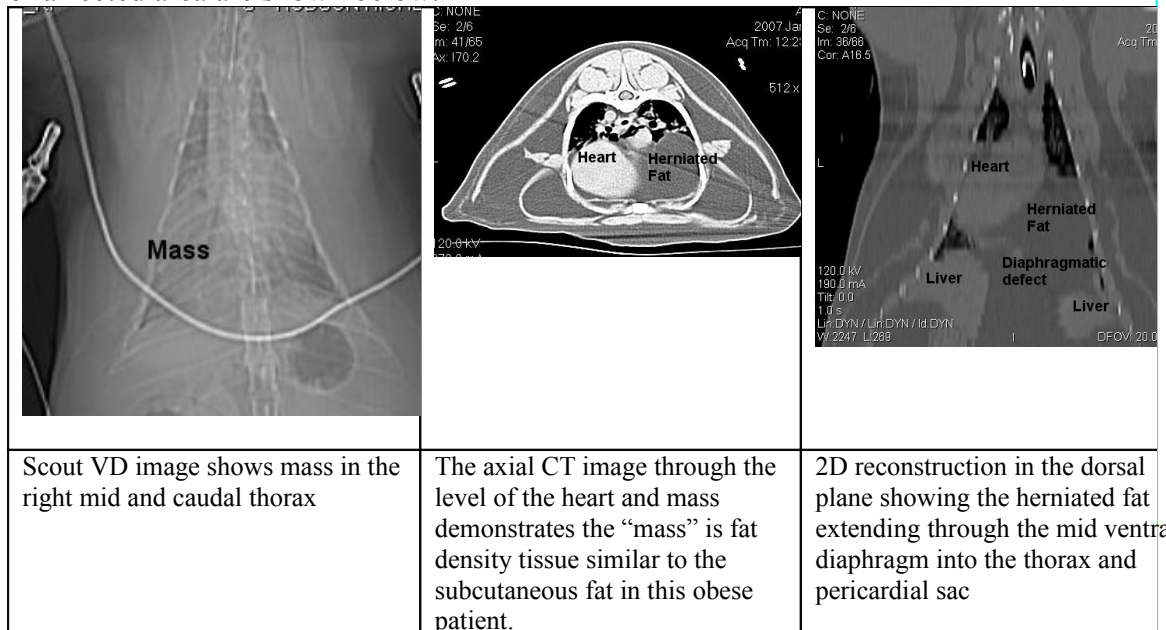
A rapid helical CT scanner completes thoracic imaging in minutes.

Case Report #10

CT for Dyspnea and Thoracic Mass lesion

Case Summary – A ten-year-old MN DSH cat presented for a one-month duration of occasional coughing, lethargy and mild dyspnea. On physical exam the pet was obese. Lung and cardiac sounds were reduced on the right. Survey radiographs revealed a mass in the right mid through caudal thorax. Neoplasia, abscess, cyst, granuloma, hematoma and sequestered fluid were considered as possible causes of the mass. A thoracic US was inconclusive.

Imaging- A thoracic CT was performed. No complications were encountered and the cat recovered uneventfully. Cross sectional imaging and multiplanar reconstructions of affected area are shown below.



Imaging Diagnosis- Obesity. Pericardioperitoneal-diaphragmatic hernia with a large amount of herniated falciform fat creating a space occupying mass effect in the right mid and caudal ventral thoracic regions, displacing and compressing the lungs dorsally.

Outcome- The prognosis is excellent based on the CT diagnosis. The owner elected to have the hernia repaired surgically and the patient did well. Weight loss was also advised.

Please do not hesitate to contact our facility to discuss the value of a CT or MRI study for a particular patient prior to requesting an imaging study.

(Tel – 973 772-9902, Fax – 973 772-9904)