

Optic Nerve Neoplasia

Case Summary: A 10 yr. old spayed female Golden Retriever was presented for MRI scanning of the head/brain to evaluate the cause of progressive vision loss in the right eye. The patient was otherwise healthy and the only other symptom reported was a ravenous appetite. The patient had also been evaluated by an ophthalmologist and had a normal fundic exam and optic pressures. The patient's exam and bloodwork were within normal limits and the patient was taking no medications at the time of the scan.

MRI and CT are very valuable in defining retrobulbar disease with MRI being indicated when there is suspected brain or optic nerve involvement

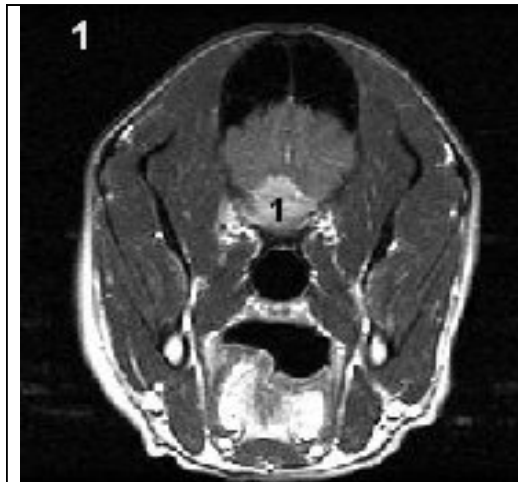


Figure 1: axial post contrast T1 image showing contrast enhancing mass (1) at the base of the brain

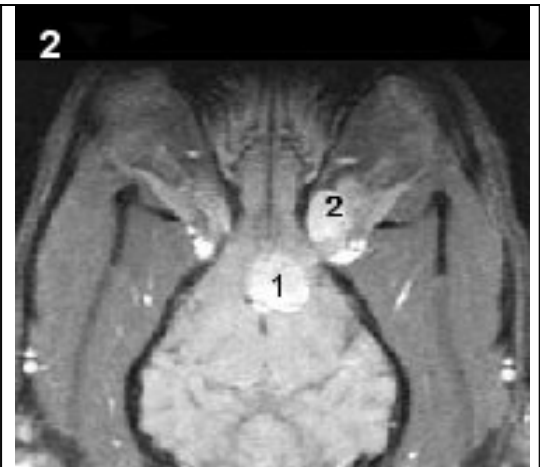


Figure 2: dorsal post contrast T1 images showing contrast enhancing mass in the retrobulbar area of the orbit (2) and a contrast enhancing mass portion in the brain (1).

Findings: A contrast enhancing v-shaped soft tissue mass was observed arising from the optic nerve. The mass extends from the area of the hypophyseal fossa and optic chiasm, rostrally through the orbital and optic canals, extending into the caudal axial aspect of the retro orbital regions. The mass also extends dorsally into the floor of the calvarium displacing and causing slight compression of the cerebrum. There is calvarial bone destruction and infiltration in the area of the mass.

Imaging Diagnosis: Findings consistent with a malignancy arising from one of the optic nerves with resultant bone infiltration. Differentials for this include soft tissue neoplasia of epithelial, hemolymphatic or connective tissue origin. Included in this list would be an optic nerve sheath meningioma, neurofibrosarcoma, glioma and less likely hemangiosarcoma.

Outcome: Based on the MRI, biopsy obtained via exenteration of the right eye could be used to reach a definitive cellular diagnosis and to determine the best treatment options. No follow up information is available at this time for this patient.

*Please do not hesitate to contact our facility to discuss the value of a CT or MRI
(Tel – 973 772-9902, Fax – 973 772-9904)*