



VETERINARY
MRI + RADIOTHERAPY
CENTER OF NEW JERSEY

MR and CT imaging allows evaluation of the external, middle and inner ear and changes in adjacent structures including the brain.

Consider cross sectional imaging in patients with disease of the ear.

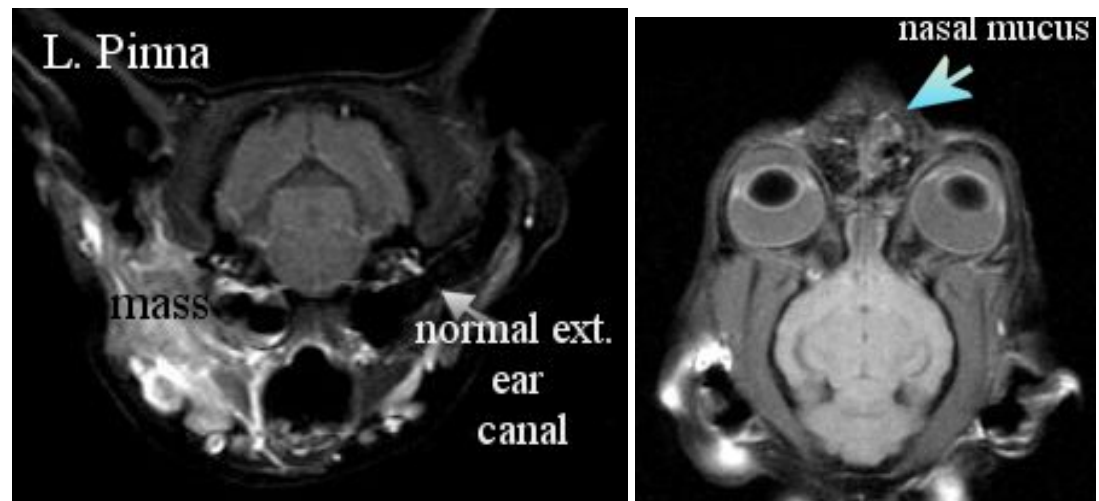
Veterinary MRI and RT Center of New Jersey

Case Report #14

MRI for Evaluating Ear Disease

Case Summary – An 11 year old spayed female indoor cat presented for acute hemorrhagic discharge from the left ear. There was no history of trauma, but the owner reported occasional clear nasal discharge for several weeks previously. Examination of the deep portion of the external ear canal was limited by bloody discharge and a narrow ear canal. Thoracic radiographs, CBC, Chem and UA results were WNL. The primary veterinarian referred the pet for MRI of the head to evaluate the deep portion of the external, middle and inner ear and nasopharyngeal regions.

Axial T1wt image post contrast (below left) through the external ear canal level. Dorsal T1wt image post contrast (below right) includes nasal region.



The MRI reveals a deep soft tissue mass invading the wall and lumen of the left external ear canal and adjacent tissues, including the parotid salivary gland and bulla. The deep medial retropharyngeal node was enlarged. There was also a bilateral increase in nasal mucus, consistent with incidental, concurrent, mild rhinitis.

Fine needle aspirates of the lesion guided by the MR images provided a cytological diagnosis of squamous cell carcinoma of the ear canal with secondary suppurative inflammation.

Comments: A CT scan could also be used to evaluate a patient with ear disease. A CT scan provides slightly less soft tissue contrast but superior bone detail. Cross sectional imaging of the head with CT and MRI is very valuable in detecting and characterizing diseases of the ear, differentiating chronic from acute conditions, assessing for bone invasion and enlargement of deep, non-palpable lymph nodes.

MRI is preferable to CT when signs of vestibular disease are present and neurological exam fails to determine if the vestibular signs are from brain or inner ear disease.

Please do not hesitate to contact our facility to discuss the value of a CT or MRI study for a particular patient prior to requesting an imaging study.

(Tel – 973 772-9902, Fax – 973 772-9904)